

Case Report

Successful Medical Management of Pediatric Gastroparesis

Mashal Ahmed, Janice Wong, Anas Shikha

*Pediatric Surgery Unit, Raja Isteri Pengiran Anak Saleha (RIPAS) Hospital, Brunei Darussalam.***Keywords**

Abdominal distension
Domperidone
Erythromycin
Gastrointestinal paralysis
Gastroparesis
Intestinal motility disorder
Prokinetic agents

Abstract

Pediatric gastroparesis is characterized by delayed gastric emptying in the absence of any mechanical obstruction. This case report describes the successful use of domperidone and erythromycin in managing refractory gastroparesis in a 7-year-old girl. Owing to its rarity and shared symptomatology with other common gastrointestinal conditions, the diagnosis of gastroparesis is often delayed. In resource-limited centers without scintigraphy, the diagnosis may be made based on the clinical features and contrast radiography.

INTRODUCTION

Gastroparesis is an uncommon condition characterized by delayed gastric emptying in the absence of any mechanical obstruction.⁽¹⁾ The symptoms include nausea, vomiting, early satiety, epigastric bloating, weight loss, and abdominal pain.⁽²⁾ Diagnosis and treatment are challenging. Management is often multimodal, including dietary changes, prokinetic medications and occasionally surgical interventions. An identifiable cause is often absent though it is more common in girls and is linked to diabetes, infections or surgery.⁽³⁾ This report is intended to draw the attention of practicing pediatric surgeons to this uncommon problem.

CASE REPORT

A 7-year-old girl presented to emergency department with abdominal pain, distension, and constipation for 2 days. Her parents reported a long-standing history of abdominal bloating without constipation over the preceding 2 yr. She was born

by normal vaginal delivery at full-term, with a birth weight of 3.5 kg. There was no significant maternal or antenatal history. During the perinatal period, she had neonatal jaundice and septic ileus that were treated conservatively.

At the age of 2 yr, she had a similar presentation with post-prandial abdominal pain, bloating and constipation for 2 weeks. Dietary modifications and laxatives relieved her symptoms. On further probing, she was found to have intermittent upper abdominal fullness since infancy, particularly after large meals with no history of vomiting, nausea, diarrhea, or fever. Stool consistency ranged from Type IV to III on the Bristol Stool Chart. Described as a 'picky eater,' she frequently consumed Milo™ and junk foods.

On physical examination, he was afebrile and well hydrated. She had moderate upper abdominal distension with no palpable fecaloma. Digital rectal examination was unremarkable.

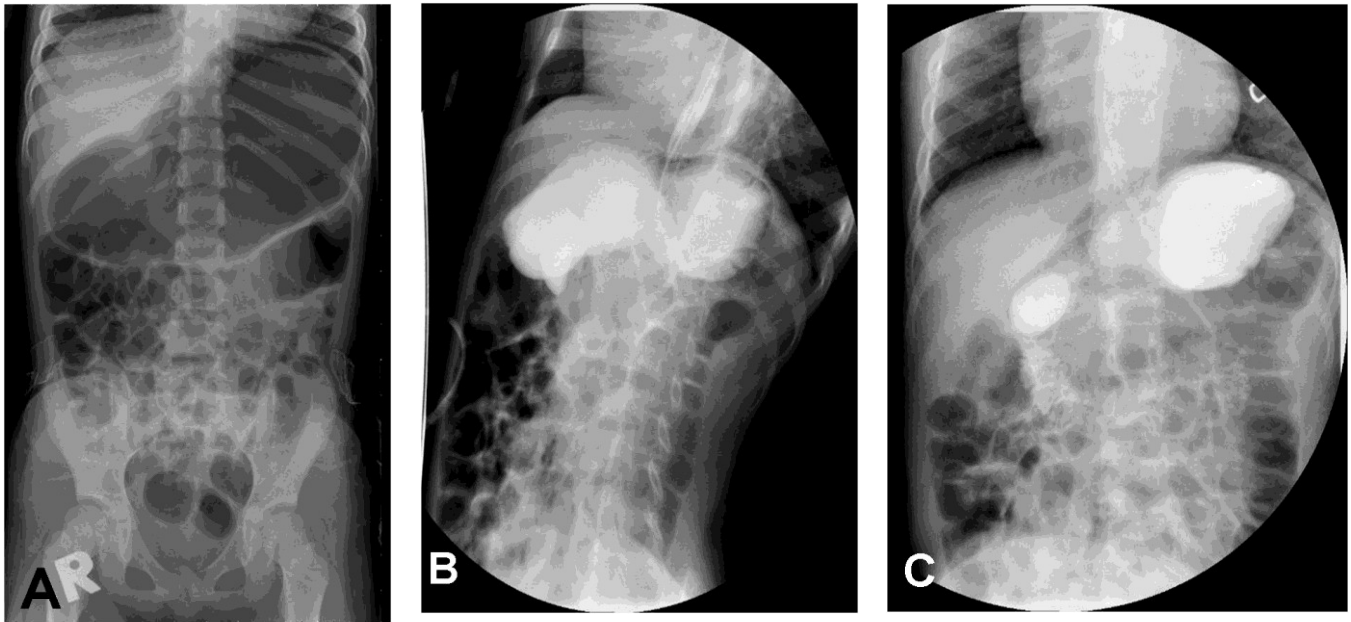


Fig 1. *Imaging studies. (A) Plain radiograph showing hugely distended stomach, (B) Upper gastrointestinal contrast study showing distended stomach, (C) Delayed contrast film showing retained contrast in the stomach even after 120 min.*

On admission, she was treated with nil per mouth, intravenous fluids and gastric decompression by a nasogastric tube. Blood work-up was unremarkable and an abdominal radiograph showed significantly dilated stomach without fecal loading. (Fig. 1) Over the next 2 days, her abdominal distension improved and oral feeding was initiated. Suspecting gastroparesis, she was given domperidone (0.5mg/kg, t.i.d) and Erythromycin (2mg/kg, t.i.d).

Upper gastrointestinal contrast study showed a distended, baggy stomach without gastric outlet obstruction or rotational anomalies. A significant amount of the contrast was found to be retained in the delayed film at 120 min. (Fig. 1)

The diagnosis of gastroparesis and its long-term treatment plan were discussed with the parents. By day-6 of admission, she was relieved of the symptoms and was discharged with domperidone, erythromycin and bisacodyl (5mg, o.d) and advice on dietary modification.

At 2 mo of follow-up, her symptoms had resolved. Bisacodyl was discontinued, and gradual weaning of other medications was planned. Erythromycin and domperidone were stopped after 6 mo and 9 mo respectively. She was well at 3 mo after stopping all medications.

DISCUSSION

Gastroparesis is diagnosed primarily by clinical features. Gastric emptying scintigraphy is the gold standard for confirmation.⁽¹⁾ When scintigraphy is unavailable, as it is in our case, upper gastrointestinal contrast radiography may be helpful. It aims to rule out other causes of gastric outlet obstruction and demonstrate a significant gastric residue even after 120 min.

Managing gastroparesis is challenging, particularly in chronic cases. First-line intervention includes dietary modifications such as low-fibre diet, small frequent meals and avoiding dairy products. While no medication is standardized, prokinetic agents and antiemetics are commonly used for sympto-

matic relief. Surgical treatment includes gastrotomy, pyloromyotomy, intra-pyloric injection of botulinum toxin, feeding jejunostomy and implantation of a gastric pacemaker.⁽¹⁾ The wide variety of treatment options underscores the lack of a consensus in the management of gastroparesis.

The aims of medical management are to relieve symptoms and to address malnutrition.^(4,5,6) This case report highlights the usefulness of a combination therapy with domperidone and erythromycin. Previous studies have focused only on erythromycin;^(5,6) but we noted that combining it with domperidone for 3-6 months gives a better result. As chronic gastroparesis is characterized by periodic exacerbations and remissions caution is needed in attributing the cure to any particular medication. Recurrence of symptoms in future cannot be ruled out and they can be treated with the same strategy. In addition to pharmacological stimulation of gastric peristalsis, addressing any concurrent constipation is essential during gastroparesis treatment. Factors that influence the resolution of symptom include the host response to treatment, timing of treatment initiation, duration of symptoms and the underlying cause of gastroparesis. In most of the cases, including our patient, response to prokinetic agents is rapid despite long duration of symptoms.

CONCLUSION

Owing to its rarity and shared symptomatology with other common gastro-intestinal conditions, the diagnosis of gastroparesis is often delayed. In resource-limited centers without scintigraphy, the diagnosis may be made based on the clinical and contrast radiography features. Combination treatment with domperidone and erythromycin seems to be effective.

REFERENCES

- [1] Camilleri M, Kuo B, Nguyen L, Vaughn VM, Petrey J, Greer K, Yadlapati R, Abell TL. ACG Clinical Guideline: Gastroparesis. *Am J Gastroenterol*. 2022 Aug 1; 117(8): 1197-1220.
- [2] Saliakellis E, Fotoulaki M. Gastroparesis in children. *Ann Gastroenterol*. 2013;26(3):204-211.
- [3] Islam S. Gastroparesis in children. *Curr Opin Pediatr*. 2015 Jun; 27(3): 377-82.
- [4] Rangan V, Ukleja A. Gastroparesis in the hospital setting. *Nutr Clin Pract*. 2021 Feb; 36(1): 50-66.
- [5] Waseem S, Islam S, Kahn G, Moshiree B, Talley NJ. Spectrum of gastroparesis in children. *J Pediatr Gastroenterol Nutr*. 2012 Aug; 55(2): 166-72.
- [6] Rodriguez L, Irani K, Jiang H, Goldstein AM. Clinical presentation, response to therapy, and outcome of gastroparesis in children. *J Pediatr Gastroenterol Nutr*. 2012 Aug; 55(2): 185-90.

Address for communication: Dr. Anas Shikha,
Email: dr.a.n.shikha@gmail.com

© Authors; Distributed under Creative Commons CC-BY-NC-ND attribution 4.0 international license

Received: 22 October 2024

Accepted: 6 December 2024

Acknowledgements : None

Conflicts of Interest : None declared by the author

Source of Funding : None

Ethical concerns : None (Reporting of routine clinical care)

Citation: Ahmed M, Wong J, Shikha A. Successful medical management of pediatric gastroparesis. *Pediatr Surg Trop* 2025; 2(1): 65-67.

<https://doi.org/10.70947/pst.2025.09>

